

Assessment of postoperative recovery and post-penopexy return of teaser bulls to natural mounting

Abarca-Acero, Mario A.^{1*}; Arieta-Román, Ronnie de J.¹; Lara-Rodríguez, Daniel Alejandro¹; Fernández-Figueroa, José A.¹

¹ Universidad Veracruzana, Facultad de Ingeniería en Sistemas de Producción Agropecuaria, Carretera Costa del Golfo km 220, Colonia Agrícola y Ganadera, Acayucan, Veracruz, México, C. P. 96100.

* Correspondence: mvzabarca87@gmail.com

ABSTRACT

Objective: To assess the perineal penopexy surgical technique in the preparation of teaser bulls for the bovine industry.

Design: To assess the technique, three 11-month-old Swiss-Zebu bovines, with an average weight of 280 kg, were subject to a surgical procedure. The assessed parameters were time of procedure, postoperative recovery (infectious processes), and return to normal mounting.

Results: This study shows a total average time —from the beginning of the procedure until the animal can stand— of 23.7 min, plus nine days of postoperative recovery, without infectious processes.

Implications: During the postoperative process, the ring might be rejected, fibrous tissue might form as a reaction to the ring's material, and the penis might be overexposed because of the ring's diameter.

Limitations: There might be limitations resulting from the surgeon's experience regarding the location of the sigmoid flexure.

Results: Using this technique contributes to the improvement of the teaser bull preparation protocols for bovine artificial insemination programs.

Key words: Animal reproduction, Estrus detection, Teaser bulls.

Citation: Abarca-Acero, M. A., Arieta-Román, R. de J., Lara-Rodríguez, D. A., & Fernández-Figueroa, J. A. (2022). Assessment of postoperative recovery and post-penopexy return of teaser bulls to natural mounting. *Agro Productividad*. <https://doi.org/10.32854/agrop.v15i11.2301>

Academic Editors: Jorge Cadena Iniguez and Libia Iris Trejo Téllez

Received: June 17, 2022.

Accepted: November 19, 2022.

Published on-line: December 20, 2022.

Agro Productividad, 15(11). November, 2022. pp: 157-163.

This work is licensed under a Creative Commons Attribution-Non-Commercial 4.0 International license.



INTRODUCTION

A series of physiological, zootechnical, and nutritional processes must be taken into consideration to improve the reproductive indicators of bovine cattle in their zootechnical function as teaser bulls. An inadequate management will result in reduced reproductive parameters. One of the most relevant variables is the length of estrus, which is represented in the production unit by its most important feature: the postpartum interval. Ideally, a bovine female in reproductive age is expected to give birth to one calf per year. Estrus detection is



one of the main problems in production units where artificial insemination programs are in place. Low estrus detection levels could impact gestation up to 90 days after the cow has given birth, as well as the service rate, both of which extend the parturition-to-conception and parturition intervals. In this context, the preparation of teaser bulls may contribute to increase estrus detection in female cows by up to 80% (Hidalgo *et al.*, 2018). Reproductive biotechnologies (*e.g.*, artificial insemination (AI)) help to improve zootechnical efficiency. AI maximizes the potential of a bull with outstanding genetic characteristics by adding a genetic value: the bull's distinctive features are expanded and assessed in the number of offspring (Rosete-Fernández *et al.*, 2019).

Reproduction is one of the most important aspects when establishing the yield rate of bovine cattle productions, both in the dairy and meat industries. The traditional methods of reproduction, feeding, and management could improve the biological and economic effectiveness of bovine cattle, through the adequate application of controlled breeding techniques (Blandón-Mairena and Blandón-Palacio, 2016).

One of the most essential stages in the artificial insemination process is observing the heat. In this regard, surgically prepared males (teaser bulls) are an important tool to increase reproductive parameters within an improvement program (Silva and Pimentel, 2017). Using a teaser bull (a sterile animal) hinders the transmission of venereal diseases, while at the same time the libido remains high (Morgan and Dawson, 2008). The techniques to prepare teaser bulls can be classified into two categories: mating and emission of semen hindering (Franco-da Silva *et al.*, 2002). Therefore, the objective of this work was to assess the perineal penopexy surgical technique to prepare teaser bulls for the bovine industry.

MATERIALS AND METHODS

The field work was conducted in three production units located in the State of Chiapas, Mexico. The Frailesca region is mainly characterized by a large agricultural activity. It is in the Sierra Madre, in the central region of Chiapas (16° 14' N, 93° 16' 09" W). It consists of 23 municipalities distributed in an area of 12,629 km² (16.7% of the state territory), which makes it one of the largest areas of the state. The regional seat is Tuxtla Gutiérrez. The surgical technique was performed on three bovine males of Swiss×Zebu genotype, with an average age of 15 months, and 280 kg of live weight. The animals were clinically healthy, in proper body condition, and sexually active.

Surgical technique

Surgical instruments: Needle holder, scalpel handle and blades, Kelly hemostatic clamps, Backhaus clamps, straight and curved scissors, hypodermic needles.

Surgical material and medications: Nylon surgical gloves. The following medications were used: 2% xylazine hydrochloride (tranquilizer), benzalkonium chloride and iodopovidone (disinfectant), 2% lidocaine (local anesthetic), Negasunt powder (healer, anti-insect repellent), 10% enrofloxacin (antibiotic), and flunixin meglumine (analgesic).

Patient preparation: The animals followed a 24 h fasting period for food and 12 h for water. They were tranquilized with 2% xylazine hydrochloride, using an intramuscular

dose of 0.05 mg kg^{-1} of live weight (the equivalent for the product's brand presentation is 0.25 mL per 100 kg of live weight).

Animal positioning: The animals were placed in the right lateral decubitus position with the limbs held separately to better expose the perineum. Before administering the anesthetic, the operation area of the body was prepared: a round area, two to three times larger than the surgical site, was washed with soap and water. Subsequently, the area was shaved with a razor blade and antisepsis was performed with benzalkonium chloride and iodopovidone (Figure 1).

Local anesthesia: To ensure the numbness of the surgical site, 2% lidocaine was used to block the area of the perineum where the incision would be made. The injection was administered subcutaneously with a 3.5-cm long 18-gauge needle.

Asepsis of the perineum: Once infiltration anesthesia had taken effect in the perineum, the disposable surgical drapes were put into place using Backhaus clamps.

First stage: To begin the surgical procedure, we protected the open area where the incision would be made with surgical drapes. Once the animal was in the lateral decubitus position, we rapidly located the sigmoid flexure of the penis with the help of an assistant.

Second stage: The penile flexure was located and held in a fixed position by an assistant, who maintained it in the distal third of the perineum, above its midline, approximately 10 cm above the scrotal neck (Figure 2).

Third stage: We made two small incisions (2 cm) on each side of the penis or median raphe.

Fourth stage: We inserted a trocar through the two lateral incisions and mounted the flexure on it (Figure 3).

Fifth stage: We removed the trocar and placed the previously disinfected nasal ring, which remained fixed once its corresponding screw was closed.

Sixth stage: Only part of the nasal ring remained exposed. The lateral wounds healed by second intention (Figure 4).

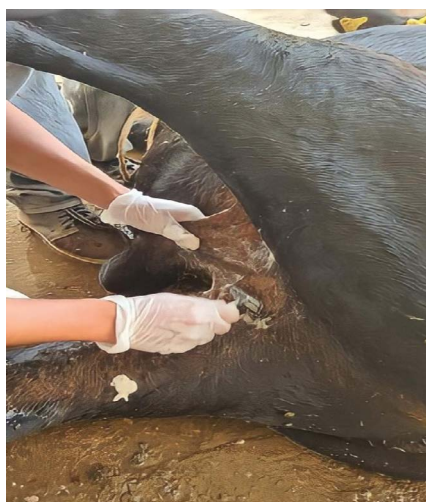

Figure 1. Preparation of the perineum with the animal in the decubitus position.

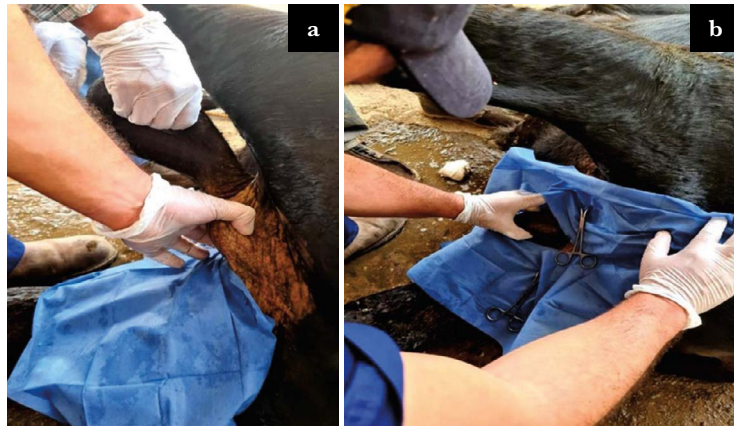

Figure 2. Identification of the sigmoid flexure. a) Palpation of the flexure, where the nasal ring will be inserted; b) placement of surgical drape.

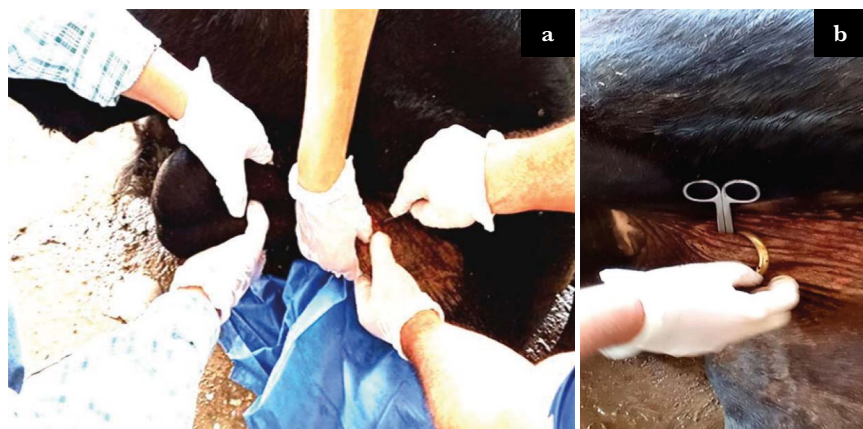


Figure 3. a) Incision on the distal part of the sigmoid flexure; b) subsequently, blunt scissors inserted through the incision served as guide for the nasal ring.



Figure 4. Nasal ring placed on the sigmoid flexure for anatomical fixation.

Seventh stage: We cleaned the surgical area with benzalkonium chloride and applied an antibiotic spray (oxytetracycline). The males that underwent surgery were kept in a clean place. Although the technique is minimally invasive, supervising cicatrization is crucial. We administered IM antibiotics for five days.

RESULTS AND DISCUSSION

Results indicated that perineal penopexy has a rapid recovery rate due to its low invasiveness. There was no significant tissue damage, and the average recovery time was eight days. According to Vizcarra *et al.* (2011), other surgical techniques used to prepare teaser bulls—such as the surgical removal of the penile dorsal apical ligament— have shown a longer recovery time.

Recovery time

Table 1 shows an average total surgery time of 23.7 min, including preoperative and intraoperative care, as well as patient recovery.

Macroscopic changes after the procedure

Table 2 shows the cardinal signs of inflammation (redness, heat, swelling, and pain).

Table 3 shows macroscopic changes on the incision site, eight days after the procedure.

Postoperative assessment at 90 days of animals that underwent surgery showed no physiological changes concerning loss of libido, and total exposure of the penis was observed. As for complications resulting from the technique, one animal presented exudative secretion that did not compromise its physiological state (Table 3). The investment required for this surgical technique is very low and all three bulls fulfilled their zootechnical function as teaser bulls (Table 4).

Table 1. Assessed indicators and average clinical results.

Animal number	Preoperative time (min)	Transoperative time (min)	Recovery time (min)
1	25	40	20
2	20	30	20
3	30	15	10
Average time	25	28.3	16.6

Table 2. Physiological indicators of inflammation.

Animal number	Blushing	Pain	Warmth	Tumor
1	Pale pink	Moderate	Moderate	Absence
2	Pale pink	Moderate	Moderate	Absence
3	Pale pink	Moderate	Moderate	Absence

Table 3. Macroscopic changes on the incision site.

Animal number	Wound healing	Macoscopic changes
1	Tissue with the presence of exudate	Presence
2	Healthy tissue	Presence
3	Healthy tissue	Presence

Table 4. Total costs of the penopexy technique in Mexican pesos (\$20.00 equivalent to one USD).

Drug/Supplies	Supplies costs (\$Mex)	Quantity	Total costs of Tx/8 days (\$Mex)
Oxytetracycline-topical antiseptic	8.6	8 atomizations	68.8
Enrofloxacin 10%	4.2	25 mL	110
Xylazine hydrochloride	3.3	2 mL	6.6
Syringes	10 each	4 pieces	40
Surgical gauze	2.2 each	10 pieces	22
18×3.2 cm gauge needles	1	8 pieces	8
Scalpel blades	8	1 piece	8
Metamizole sodium	0.7	60 mL	42
Povidone-iodine	1.7	10 mL	17
Benzalkonium chloride	0.02	200 mL	4
Copper ring	170	1	170
Total			496.4

CONCLUSIONS

The results of this study uphold our conclusion that the perineal penopexy surgical technique is highly efficient in the preparation of teaser bulls. It is minimally invasive, the surgery time is short, and the investment required to prepare males decreases. Moreover, it presents a favorable recovery rate: animals are ready to fulfill their corresponding zootechnical function within a 15-day period.

ACKNOWLEDGEMENTS

We would like to thank CONACyT for providing a master's degree grant in M. A. A. We also thank the owner of Rancho San Judas Tadeo, Mr. Ain Palacios Sánchez (DVM), and the School of Veterinary Medicine and Zootechnics at the Universidad Nacional Autónoma de Chiapas (UNACH).

REFERENCES

- Blandón-Mairena, E. W., & Blandón-Palacios, A. C. (2016). Caracterización del manejo zootécnico de la unidad de producción bovina en la finca Santa Rosa de la Universidad Nacional Agraria. Tesis doctoral, Universidad, Nacional Agraria, Managua, Nicaragua. 59 p.
- Franco-da Silva, L. A., Martins-Chaves, S., Soares-Fioravanti, M. C., Eurides, D., & Rabelo, R. E. (2002). Complicações decorrentes da utilização da acepromazina associada à xilazina na preparação cirúrgica de rufiões bovinos. *Ciência Rural*, 32(3), 439-444. <https://doi.org/10.1590/S0103-84782002000300012>
- Hidalgo, V. Y., Carlomagno-Velásquez, V., Chagray, A. N., Llapapasca, G. N., & Delgado, C. A. (2018). Relación entre dos métodos de detección del celo y eficiencia reproductiva en vacas Holstein. *Revista de Investigaciones Veterinarias del Perú*, 29(4), 1364-1371. <http://dx.doi.org/10.15381/rivep.v29i4.15388>

- Morgan, G. L., & Dawson, L. J. (2008). Development of teaser bulls under field conditions. *Veterinary Clinics Food Animal Practice*, 24(1), 443-453. <http://dx.doi.org/10.1016/j.cvfa.2008.06.004>
- Rosete-Fernández, J. V., Álvarez-Gallardo, H., Urbán-Duarte, D., Fragoso Islas, A., Asprón-Pelayo, M. A., Ríos-Utrera, Á., Pérez-Reynoso, S., & de la Torre-Sánchez, J. F. (2021). Biotecnologías reproductivas en el ganado bovino: cinco décadas de investigación en México. *Revista Mexicana de Ciencias Pecuarias*, 12(3), 39-78. <https://doi.org/10.22319/rmcp.v12s3.5918>
- Silva, M. A. M., & Pimentel, L. A. (2017). Mejoramiento genético en bovinos a través de la inseminación artificial y la inseminación artificial a tiempo fijo. *Revista de Investigación Agraria y Ambiental*, 8(2), 247-259. <https://doi.org/10.22490/21456453.2050>
- Vizcarra, G. V. M., Sierra, L. E. M., Eroles, V. J. A., & Puerto, N. J. L. (2011). Preparación de toros celadores mediante la resección del ligamento apical dorsal del pene. *Bioagrobiencias*, 4(1), 45-48.

