

Exploratory study: testicular microlithiasis in cattle from the Costa Chica region

Saavedra-Jiménez, Luis A.; Olvera-Ramírez, José F.; Núñez-Martínez, Guadalupe; Bottini-Luzardo, María*

Universidad Autónoma de Guerrero, Facultad de Medicina Veterinaria y Zootecnia No. 2. Carretera Acapulco-Pinotepa Nacional km 197, Cuajinicuilapa, Guerrero, México, C. P. 41940.

* Correspondence: 17906@uagrop.mx

ABSTRACT

Objective. To determine the presence of microlithiasis in bulls from the Costa Chica, Guerrero, Mexico, and to assess the sperm quality of the bulls affected by this pathology.

Methodology. Seventy-seven bulls were assessed in four municipalities of the state of Guerrero, Mexico. Bull testicles were subjected to an ultrasonography test and, in the event of microlithiasis, they were classified according to the number of points observed. In addition, semen was collected by electroejaculation. Sperm concentration ($\times 10^6$ sperm mL^{-1}) and individual motility (%) were quantified from the samples. Microlithiasis results are expressed as a percentage of the total number of assessed animals. Seminal characteristics were subjected to an ANOVA and the means were compared using the Tukey test.

Results. Approximately 25% of the assessed individuals showed microlithiasis. About 60% of such cases were classified as grade 2 (>5 , <25 points). Three microlithiasis grades were identified in Brown Swiss bulls, while in Gyr bulls no grade was identified. Regarding seminal characteristics, in average, the overall sperm concentration was 992.5×10^6 sperm mL^{-1} and the overall individual motility was 75.5%. The bull breed variable did not generate statistical differences in the seminal quality variables.

Conclusion. The presence of microlithiasis was identified in bulls from the Costa Chica region in Guerrero; however, sperm concentration and individual motility were not affected.

Key terms: Testicular diseases, ultrasound scan, semen.

Citation: Saavedra-Jiménez, L. A., Olvera-Ramírez, J. F., Núñez-Martínez, G., & Bottini-Luzardo, M. (2022). Exploratory study: testicular microlithiasis in cattle from the Costa Chica region. *Agro Productividad*. <https://doi.org/10.32854/agrop.v15i4.2131>

Academic Editors: Jorge Cadena Iñiguez and Libia Iris Trejo Téllez

Received: September 23, 2021.

Accepted: March 7, 2022.

Published on-line: May 9, 2022.

Agro Productividad, 15(4). April. 2022. pp: 89-94.

This work is licensed under a Creative Commons Attribution-Non-Commercial 4.0 International license.



INTRODUCTION

During the selection of the breeding male, particular attention should be paid to the ejaculated semen quality (Kabiraj *et al.*, 2011) which determines the fertilizing capacity (Großfeld *et al.*, 2008). The conditions that can affect bull fertility include pathologies such as testicular microlithiasis (Chandolia *et al.*, 2018). This condition is defined as calcifications found in the seminiferous tubules (Tan and Eng, 2011). It can be observed in ultrasonography test as small hyperechoic spots in the testicular parenchyma (Yee *et al.*, 2011); their etiology is yet unknown (Pedersen *et al.*, 2019).



In case of animals of zootechnical interest, this pathology can be considered an incidental finding when bulls are assessed (Chandolia *et al.*, 2018). One of the concerns arising from this pathology is its potential effect on spermatogenesis (Sihag *et al.*, 2018), sperm quality, and testosterone concentration. Recent studies in humans have found an inversely proportional relationship between microlith presence and sperm quality (Xu *et al.*, 2014).

In Mexico, cattle raising is the second most widespread productive activity in rural areas (Rodríguez Mejía *et al.*, 2018). However, meat and milk production levels are not optimal. A similar situation is found in the Costa Chica region of the state of Guerrero, where livestock is developed under tropical conditions, free grazing prevails, and reproductive programs are based on natural mating. To improve productive and reproductive indexes, the bulls with the best semen characteristics should be identified, avoiding breeders with low fertility or testicular tissue diseases. Therefore, the objective of this study was to determine whether or not microlithiasis is found in bulls from the Costa Chica in Guerrero, Mexico and to assess the sperm quality of males affected with such pathology.

MATERIALS AND METHODS

Location

The study was performed in four municipalities of the Costa Chica region, in the state of Guerrero, Mexico (Azoyú, Cuajinicuilpa, Ometepec, and San Marcos). The region has a predominately warm sub-humid climate with rains in summer, and temperature fluctuates between 22 and 28 °C. Precipitation ranges from 1200 to 2000 mm.

Assessed animals

From July 2018 to July 2019, seventy-seven bulls (*Bos indicus*, *Bos taurus*, and *Bos indicus* × *Bos taurus*) from six different breeds were assessed (Table 1). The following inclusion criteria were used: age ≥ 16 months; and body condition ≥ 4, on a scale from 1 (emaciated) to 9 (obese) (Ayala-Burgos *et al.*, 1998). The scrotal circumference was measured using a scrotimeter, in order to verify that it was appropriate for their race and age (Momont and Checura, 2015). A full clinical evaluation was performed to rule out the presence of reproductive pathologies that could affect the testicles or sperm quality.

Table 1. Analyzed bulls grouped by breed and place of origin.

Breed	Municipality			
	Azoyú	Cuajinicuilpa	Ometepec	San Marcos
Brahman	4	6	3	8
Gyr	-	4	1	3
Gyr-Holando	-	-	-	2
Sardo Negro	-	7	-	2
Suiz-Bú	1	4	-	5
Brown swiss	3	5	11	8

In general, bulls are kept under grazing conditions, with mineral salt and water supplied *ad libitum*. As health measures, farmers apply vaccines against rabies, tuberculosis, and other diseases, according to the official vaccination plans established by the regional health authorities.

Testicles ultrasound examination

Testicular parenchyma was evaluated in the dorsoventral and mediolateral direction as indicated by the Momont and Checura methodology (2015), using an ultrasonograph (Chison Eco 5, China with a 7.5-MHz linear transducer). In the event of testicular microlithiasis, it was classified using a scale from 1 to 3, where 1 represents <5 hyperechoic points, 2 represents 5-25 hyperechoic points, and 3 represents >25 hyperechoic points (Amarawardena and Siyambalapitiya, 2016).

Semen collection and assessment

Semen was gathered using an electroejaculation equipment (Standard Precision, USA), collecting only the portion rich in spermatozoa. Sperm concentration was estimated using a Neubauer chamber, with the technique described by Dearing *et al.* (2014). Individual motility (IM) was evaluated by placing a semen drop under a cover slip, using a 40X objective and observing several fields. IM was quantified on a 1-100% scale (a uniform rectilinear motion), according to the Páez-Barón and Corredor-Camargo (2014) technique.

Statistical analysis

The microlithiasis incidence is showed as a percentage of the total number of animals involved in the study.

Semen quality data was subject to an analysis of variance using an unbalanced completely randomized design. The independent variable was the bull breed (Brahman, Gyr, Girolando, Sardo Negro, Suiz-Bu, and Brown Swiss), and the response variables were sperm concentration and individual motility. Treatment means (bull breed) were compared with Tukey's test ($\alpha=0.05$). All statistical analyzes were performed with the SAS software.

Ethics standards compliance

No animal testing was involved in this work, and it was performed in accordance with procedures accepted by the Universidad Autónoma de Guerrero.

RESULTS AND DISCUSSIONS

Table 2 shows the percentage of individuals in which microlithiasis was identified, as well as the microlithiasis degree, based on the number of hyperechoic points observed (Figure 1a-c). Out of the total assessed animals, 24.7% showed some microlithiasis degree. More than 50% of the total number of animals in which microlithiasis was identified belong to degree 2 (Figure 1b). The most affected breed was the Brown Swiss breed (57.9% of the observed cases), followed by the Brahman breed (26.3%). Likewise, the Brown Swiss breed was the only one in which the 3 microlithiasis degrees were observed (Figure 1c).

Table 2. Microlithiasis percentage in bulls from different breeds used in the Costa Chica, Guerrero, Mexico.

Breed	N	Age (months) Mean \pm SD	Microlithiasis ^z			
			NI	1	2	3
Brahman	21	37.1 \pm 17.12	20.8	5.2	1.3	-
Gyr	8	41.8 \pm 20.19	10.4	-	-	-
Gyr-Holando	2	48.0 \pm 0.00	1.3	-	1.3	-
Sardo Negro	9	29.8 \pm 7.79	11.7	-	-	-
Suiz-bú	10	38.0 \pm 23.32	10.4	1.3	1.3	-
Brown Swiss	27	39.1 \pm 24.48	20.8	2.6	10.4	1.3

^z Microlithiasis degree: Degree 1, <5 hyperechoic points; Degree 2, 5-25 hyperechoic points; and Degree 3, >25 hyperechoic points.

Table 3 shows the means of sperm concentration ($\times 10^6$ sperm mL^{-1}) and individual motility (IM, %) observed in cattle of different breeds in the Costa Chica. The overall average for sperm concentration was $992.5 \pm 782.5 \times 10^6$ sperm mL^{-1} , with a range between 25.0 and 2375×10^6 sperm mL^{-1} . Moreover, the individual motility percentage had an average of $75.5 \pm 23.54\%$, with a range between 10 and 98%. Gyr and Brahman bulls showed the highest magnitude values for both characteristics. The bull breed variable did not generate a statistical difference with regard to sperm concentration ($p=0.4531$) or individual motility ($p=0.4531$).

The microlithiasis presence in the testicular tissue is uncommon and even rare (Chandolia *et al.*, 2018); it is usually reported as an incidental finding. In human males, Furness *et al.* (1998) and Catanzariti *et al.* (2014) have reported between 0.6% and 12.7% microlithiasis presence, respectively; those percentages are lower than those obtained in this study. In case of animals of zootechnical interest, this pathology has been identified in goats, rabbits, horses (McEntee, 1990), and buffalo (Chandolia *et al.*, 2018); this pathology

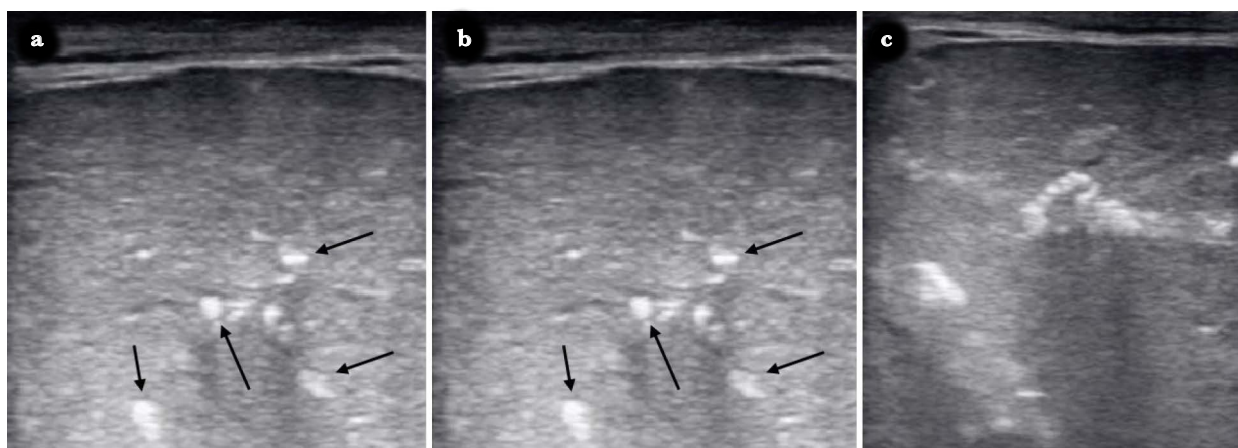


Figure 1. Testicular microlithiasis degree according to the number of observed hyperechoic points. a. Degree 1, <5 hyperechoic points. b. Degree 2, 5-25 hyperechoic points. c. Degree 3, >25 hyperechoic points. In a and b, the arrows indicate the microliths.

Table 3. Sperm concentration and individual motility in bulls from different breeds used in the Costa Chica, Guerrero, México.

Breed	n	Age (months)	Sperm concentration (1×10^6 sperm mL ⁻¹)	Individual motility (%)
Brahman	7	38.7±11.8	1150.0±791.7 a	84.7±7.3 a
Gyr	2	50.5±30.4	1875.0±707.1 a	87.5±3.5 a
Sardo Negro	4	24.8±9.4	756.3±821.9 a	46.7±5.8 a
Suiz-Bú	6	36.8±31.4	808.3±827.9 a	70.0±30.8 a
Brown swiss	11	34.0±14.7	918.2±763.2 a	73.0±26.2 a

Means ± SD with the same letters indicate that there is no statistical difference (Tukey, 0.05).

was recorded in 33% of the analyzed cases of the latter species—a higher value than that obtained in this research. However, no studies showing the presence of this pathology in cattle were identified, because the testicular tissue examination is generally performed by manual palpation, a low sensitivity procedure that does not provide a comprehensive diagnosis.

In this study, the sperm concentration obtained was higher than 700×10^6 sperm mL⁻¹ and, in most cases, individual motility was higher than 50%. These values are considered normal and are higher than the ranges reported by Páez-Barón and Corredor-Camargo (2014) and Vélez-Castañeda *et al.* (2014). The differences may be related to the age range and the bull management in the various studies. The number of individuals analyzed does not allow to establish a final conclusion regarding whether or not the breed creates a statistical difference on the analyzed semen characteristics; however, evidence suggests that breed is not a variation source for the said characteristics (Orantes *et al.*, 2010; Vélez-Castañeda *et al.*, 2014).

CONCLUSIONS

The results obtained in this research show the presence of microlithiasis in bulls from the Costa Chica region, Guerrero, Mexico. However, no decrease in the mean values of sperm concentration or individual motility was observed. More studies are necessary—with a larger size of the studied population as well as more seminal variables—in order to identify factors that favor microlithiasis development in that region and to study the relationship of this pathology with other seminal quality and fertility parameters.

CONFLICT OF INTEREST

The authors declare and agree with the information submitted in this article and accept the order of appearance in the document. There is no conflict of interest to declare.

ACKNOWLEDGEMENTS

The authors would like to thank the academic group UAGro-CA-193 “Physiology and Animal Production” for financing the development of this research.

REFERENCES

- Amarawardena, W., & Siyambalapatiya, S. (2016). Testicular microlithiasis. *Sri Lanka Journal of Diabetes Endocrinology and Metabolism*, 6(1), 36-38. <http://doi.org/10.4038/sjdem.v6i1.7305>
- Ayala-Burgos, A., Honhold, N., Delgado, R., & Magaña, J. (1992). *A visual condition scoring scheme for Bos indicus and crossbred cattle*. In: Dual purpose cattle research, 1a ed.; Anderson, S., & Wadsworth, J., Eds., Universidad Autónoma de Yucatán: Merida, México. pp. 119-128. <http://doi.org/10.13140/RG.2.1.1698.8005>
- Catanzariti, F., Cantoro, U., Lacetera, V., Muzzonigro, G., & Polito, M. (2014). Testicular microlithiasis and dyspermia: Is there any correlation? *Archivio Italiano di Urologia e Andrologia*, 86(1), 20-22. <https://doi.org/10.4081/aiua.2014.1.20>
- Chandolia, R. K., Singh, G., Kumar, A., Dutt, R., & Tiwari, D. K. (2018). Testicular microlithiasis in a buffalo bull. *Haryana Veterinarian*, 57(1), 122-123.
- Dearing, C. G., Kilburn, S., & Lindsay, K. S. (2014). Validation of the sperm class analyser CASA system for sperm counting in a busy diagnostic semen analysis laboratory. *Human Fertility*, 17(1), 37-44. <https://doi.org/10.3109/14647273.2013.865843>
- Furness, P. D., Husmann, D. A., Brock, J. W., Steinhardt, G. F., Bukowski, T. P., Freedman, A. L., Silver, R. L., & Cheng, E. Y. (1998). Multi-institutional study of testicular microlithiasis in childhood: A benign or premalignant condition? *The Journal of Urology*, 160(3II), 1151-1154. [https://doi.org/10.1016/S0022-5347\(01\)62723-X](https://doi.org/10.1016/S0022-5347(01)62723-X)
- Großfeld, R., Sieg, B., Struckmann, C., Frenzel, A., Maxwell, W. M. C., & Rath, D. (2008). New aspects of boar semen freezing strategies. *Theriogenology*, 70(8), 1225-1233. <https://doi.org/10.1016/j.theriogenology.2008.07.017>
- Kabiraj, S. K., Hoque, S. A. M., Khandoker, M. A. M. Y., & Husain, S. S. (2011). Testicular biometry and its relationship with body weight and semen output of black Bengal bucks in Bangladesh. *Journal of Cell and Animal Biology*, 5(2), 27-32. <https://doi.org/10.5897/JCAB.9000146>
- McEntee, K. (1990). *Scrotum, spermatic cord and testis: Degenerative and inflammatory lesion*. In: Reproductive pathology of domestic mammals, 1a ed.; McEntee, K., Ed.; Academic Press Inc.: San Diego, CA., USA. pp. 252-278.
- Momont, H., & Checurea, C. (2015). *Ultrasound evaluation of the reproductive tract of the bull*. In: Bovine Reproduction, 1a ed.; Wiley B., Ed.; Veterian Key: Madison, Wisconsin, USA. pp. 79-91.
- Orantes, Z. M. A., Manzur, C. A., Ruiz, R. J. L., Sánchez, M. B., Cruz, L. J. L., Ortega, J. E., Vilaboa, A. J., & Córdoba, A. V. (2010). Evaluación de sementales bovinos en el programa "Ganado Mejor" de la región Centro de Chiapas, México. *Quehacer Científico en Chiapas*, 1(10), 34-38.
- Páez-Barón, E. M., & Corredor-Camargo, E. S. (2014). Evaluación de la aptitud reproductiva del toro. *Ciencia y Agricultura*, 11(2), 49-59. <https://doi.org/10.19053/01228420.3837>
- Pedersen, M. R., Møller, H., Rafaelsen, S. R., Møller, J. K., Osther, P. J. S., & Vedsted, P. (2019). Association between risk factors and testicular microlithiasis. *Acta Radiologica Open*, 8(9), 1-6. <https://doi.org/10.1177/2058460119870297>
- Rodríguez-Mejía, S., Flores-Sánchez, D., León-Merino, A., Pérez-Hernández, L. M., & Aguilar-Ávila, J. (2018). Diagnosis of beef production systems for meat in Tejupilco, State of Mexico. *Revista Mexicana de Ciencias Agrícolas*, 9(2), 465-471.
- Sihag, P., Tandon, A., Pal, R., Jain, B. K., Bhatt, S., Kaur, S., & Sinha, A. (2018). Sonography in male infertility: A look beyond the obvious. *Journal of Ultrasound*, 21(3), 265-276. <https://doi.org/10.1007/s40477-018-0294-5>
- Tan, M. H., & Eng, C. (2011). Testicular microlithiasis: Recent advances in understanding and management. *Nature Reviews Urology*, 8(3), 153-163. <https://doi.org/10.1038/nrurol.2011.1>
- Vélez-Castañeda, L., Rugelez-Pinto, C., & Vergara-Garay, O. (2014). Effect of breed on the reproductive traits of bulls managed in extensive systems. *Revista Científica*, 25(4), 341-346.
- Xu, C., Liu, M., Zhang, F. F., Liu, J. L., Jiang, X. Z., Teng, J. B., Xuan, X. J., & Ma, J. L. (2014). The association between testicular microlithiasis and semen parameters in Chinese adult men with fertility intention: Experience of 226 cases. *Urology*, 84(4), 815-820. <https://doi.org/10.1016/j.urology.2014.03.021>
- Yee, W. S., Kim, Y. S., Kim, S. J., Choi, J. B., Kim, S. I., & Ahn, H. S. (2011). Testicular microlithiasis: Prevalence and clinical significance in a population referred for scrotal ultrasonography. *Korean Journal of Urology*, 52(3), 172-177. <https://doi.org/10.4111/kju.2011.52.3.172>